



PATIENT

Chloe Trusiewicz

SPECIES

Canine

BREED

Shih Tzu

SEX

Female Spayed

AGE

10 years

WEIGHT

12lbs

INTERPRETED BY

Maggie Machen Lamy, DVM DACVIM (Cardiology)

PRESENTING CLINICAL SIGNS

History: Recheck echo. History chronic valvular disease - Stage B2. Current presentation: No coughing noted, normal respirations. Chloe did have a collapse episode about a year ago but none since. On auscultation: NSR, grade IV/VI murmur with PMI left apical area radiating to right, PSS, lung fields clear. BP: 110mmHg x 5.

-Current medications: 1) Pimobendan/vetmedin 1.25mg - 1, 1/4 tabs twice a day---giving 2.5mg, 1/2 tab twice a day.

-Pertinent previous echo findings (3/23/21 MML): LA 2.3 cm; LA:Ao 1.7; LV 2.4 cm; moderate LAE; moderate, ecc. MR; mild TR (3.3 m/s; 44 mmHg); mild PAH *No sedation for study

- Pertinent previous echo findings (3/23/21 MML): LA 23 cm; LA:Ao 1.7; LV 2.4 cm; moderate LAE; moderate MR; mild TR (3.3 m/s; 44 mmHg); mild PAH.

ECHOCARDIOGRAM FINDINGS

2D, m-mode, color flow and Doppler imaging is available.

Left ventricle: The LV diameter is mildly increased with hyperdynamic function. LV wall thicknesses are normal.

Left atrium: The left atrium is moderately dilated.

Mitral valve: The mitral valve is diffusely thickened with mild prolapse into the left atrial lumen. Moderate eccentric mitral regurgitation with a normal velocity.

Aortic valve/Aorta: The aortic valve is normal in morphology and mobility. Normal aortic outflow velocity; laminar flow. No aortic insufficiency.

Right ventricle: Normal right ventricular diameter and morphology indicating no overt evidence of pulmonary arterial hypertension.

Right atrium: Normal RA dimension.

Tricuspid valve: The tricuspid valve appears mildly thickened with mild tricuspid regurgitation. Velocity with mild pulmonary hypertension.

Pulmonic valve/Pulmonary artery: The pulmonic valve is normal in morphology and mobility. No pulmonic insufficiency. Normal RVOT velocity; laminar flow.

Pericardium/other: No pericardial or pleural effusion noted. No obvious cardiac masses.

2-Dimensional Measurements

Ao diam (cm)	1.4
LA diam (cm)	2.4
LA:Ao (Swe)	1.7
IVS thickness (cm)	0.7
LVID diastole (cm)	2.3
PW thickness (cm)	0.7
LVID systole (cm)	1.0
FS (%)	5.7

Doppler Measurements

PV Vmax (m/s)	0.76
AoV Vmax (m/s)	1.2
MR Vmax (m/s)	5.0
TR Vmax (m/s)	3.0
TR PG (mmHg)	36

IMAGING PERFORMED BY

Pamela Harrigan, RDCS

HOSPITAL NAME

Mass Veterinary Services

REFERRING VET

Dr. Masloski

INVOICE

22777

DATE

2/23/22

INTERPRETATION OF THE FINDINGS

Chronic degenerative valve disease persists with evidence of stability. Moderate mitral and mild tricuspid regurgitation are unchanged without significant progression in left heart dimensions. Pulmonary pressures remain mildly elevated, and no additional issues are identified.

Given these findings, continue Pimobendan as previously prescribed. Continued assessment of progression in the future will help predict long term outcome, however prognosis is guarded at this stage (B2).



PATIENT

Chloe Trusiewicz

SPECIES

Canine

BREED

Shih Tzu

SEX

Female Spayed

AGE

10 years

WEIGHT

12lbs

INTERPRETED BY

Maggie Machen Lamy, DVM
DACVIM (Cardiology)

IMAGING PERFORMED BY

Pamela Harrigan, RDCS

HOSPITAL NAME

Mass Veterinary Services

REFERRING VET

Dr. Masloski

INVOICE

22777

DATE

2/23/22

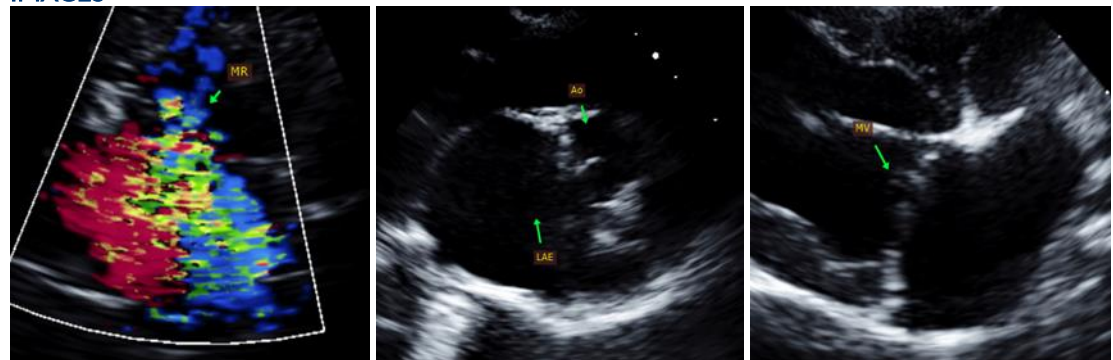
RECOMMENDATIONS

- Continue Pimobendan as prescribed.
- Omega fatty acid supplementation and mild salt restriction may be of some long-term benefit.
- Anesthetic risk is considered mild if needed. Cardiac protective drug choices (opioid/benzodiazepine premedication, propofol or alfaxalone induction, isoflurane gas) are recommended. Pre-oxygenate for 5-10 minutes prior to induction. Monitor for arrhythmias, hypotension, and hypoxia both intra and post-operatively and intervene as necessary. Mild IV fluid restriction is recommended to avoid fluid overload. Avoid heart rate stimulating drugs such as atropine unless clinically indicated.
- Monitor for development of a cough, labored breathing, exercise intolerance or collapse episodes.

PLAN

- Recommend conservative monitoring with a recheck echocardiogram in 6 months, sooner if any development of clinical signs.

IMAGES



The information and recommendations provided are based on the images presented by the referring veterinarian. No evaluation can be communicated regarding pathology that was not visible in the image/video clips provided.

Thank you for this referral. This report was generated using transcription software, and minor dictation errors may be present. If the clinical or image interpretation does not parallel your findings or if I can be of any further assistance, please contact me.

Maggie Machen Lamy, DVM
Diplomate of the American College of Veterinary Internal Medicine (Cardiology)
info@sonopath.com

Echocardiogram performed by:

Pamela Harrigan, RDCS
Pet Animal Ultrasound Service (4paus.com)